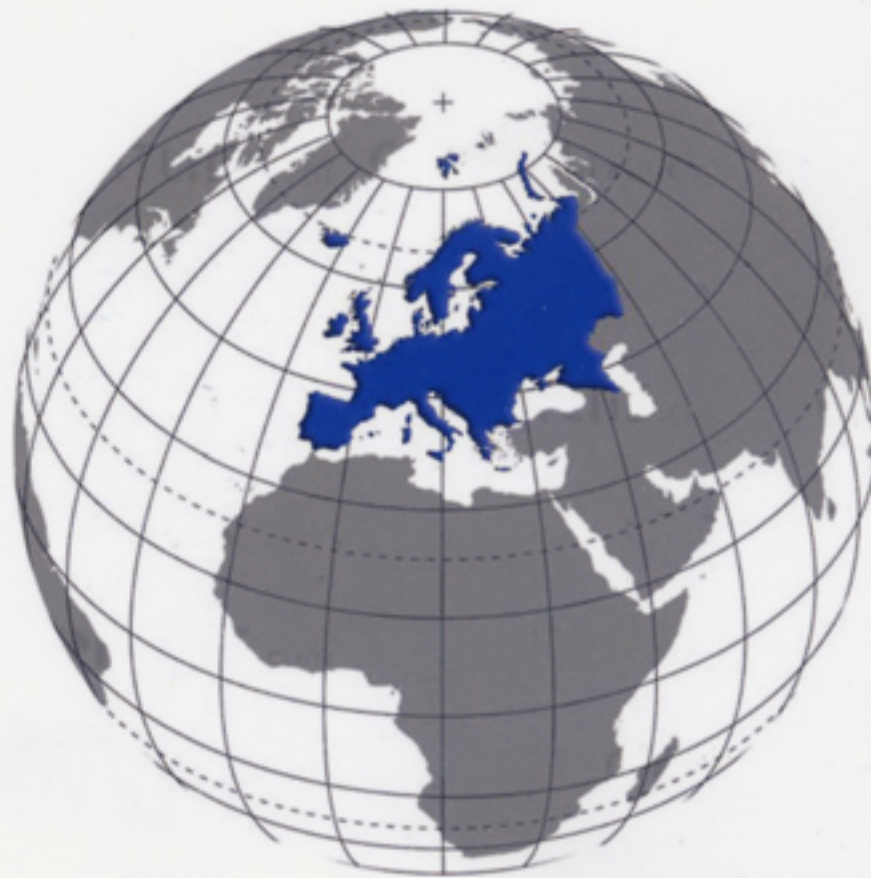

EJAMeD

www.ejamed.com

The European Journal of
Aesthetic Medicine and Dermatology



Non surgical reduction of buffalo hump deformity. Case report and letterature review

Raffaele Rauso MD

Consultant Aesthetic & Maxillo-Facial Surgery, Centro Polispecialistico Santa Apollonia, S.M.C.V. (CE), Italy

ABSTRACT

Introduction: One medication-associated condition that has become prevalent among HIV-infected patients is HIV-associated lipodystrophy. Clinically the condition manifests as body fat redistribution characterized by both lipoatrophy in the face and extremities and lipohypertrophy in such areas as the dorso-cervical region (buffalo-hump deformity), lower abdomen, and breast (breast enlargement or gynecomastia). Buffalo hump deformity treatment is challenging, in literature there are several reports about surgical treatment but, to our knowledge, effective non surgical strategies are not reported. Author describe the first report of buffalo hump deformity treated with an injective technique called "intralipotherapy" using an adipocytolytic solution.

Material and methods: A 52-years old Caucasian man, HIV positive in highly active anti-retroviral therapy treatment for 12 years prior to presentation, was referred to my office for management of lipodystrophy. Patients refused surgery. As alternative treatment the "intra-lipotherapy" for buffalo hump reduction was proposed.

Results: Not major, nor minor complication were registered. Clinical improvement was documented by photos and was reported by the patient after each treatment.

Conclusion: To our knowledge this is the first report of a buffalo hump deformity treated with the technique called "intralipotherapy", so in selected cases, when patient refuse surgical treatment, the use of this alternative technique seems to be a safe way to reduce hypertrophied dorsocervical fat pad.

KEYWORDS: lipodystrophy, HIV, Aqualyx, Intralipotherapy, Buffalo Hump deformity, localized adiposity

Eur. J. Aesth. Medicine and Dermatology. 2011;1;(1):29-34

INTRODUCTION

The development of effective antiretroviral therapies for the treatment of human immunodeficiency virus (HIV)

has drastically changed management for infected patients⁽¹⁾, with treatment approaches now similar to those of chronic

CORRESPONDENCE

Raffaele Rauso, MD
c/o Centro Polispecialistico Santa Apollonia
Via Martiri del Dissenso, 47
81055-S. Maria C. V. (CE) - Italy
raffaellerauso@virgilio.it

DISCLOSURES

Author disclose any commercial associations or financial disclosures that might pose or create a conflict of interest with information presented in the manuscript.

disease rather than fatal illness. As rates of opportunistic infections and other conditions associated with immunodeficiency are minimized, patients are able to live longer, more fulfilled lives. However, these therapies are not without side effects, some of which can be quite debilitating. One medication-associated condition that has become prevalent among HIV-infected patients is HIV-associated lipodystrophy, a syndrome characterized by abnormal fat metabolism and deposition⁽²⁾. Rates of lipodystrophy have been reported in 18% to 70% of patients taking protease inhibitors⁽³⁾.

Clinically, the condition manifests as serum metabolic abnormalities and body fat redistribution characterized by both lipoatrophy in the face and extremities and lipohypertrophy in such areas as the dorso-cervical region (buffalo-hump deformity), lower abdomen, and breast (breast enlargement or gynecomastia). These physical manifestation of the condition can have a significant psychological impact on affected patients, both in serving as a visible reminder of the disease and in association with the social stigma of HIV infection⁽⁴⁾.

Buffalo hump deformity treatment is challenging, in literature there are several reports about surgical treatment but, to our knowledge, effective non surgical strategies are not reported.

Author describe the first report of buffalo hump deformity treated with injection of an aqueous micro-gelatinous solution to induce adipocytolysis.

CASE REPORT

A 52-years old Caucasian man, HIV positive in HAART (Highly Active Anti-Retroviral Therapy) treatment for 12 years prior to presentation, was referred to my office for management of lipodystrophy. He showed facial lipoatrophy (grade 3 in James facial lipoatrophy severity scale) and a mild buffalo hump deformity. After physical examination, liposuction of the dorsocervical fat pad, and structural fat graft of the face was proposed, but patients refused surgery. As alternative treatment, polyacrilamide gel injection for facial wasting rehabilitation, and the injection of an aqueous micro-gelatinous solution (Aqualyx®) for buffalo hump treatment were proposed.

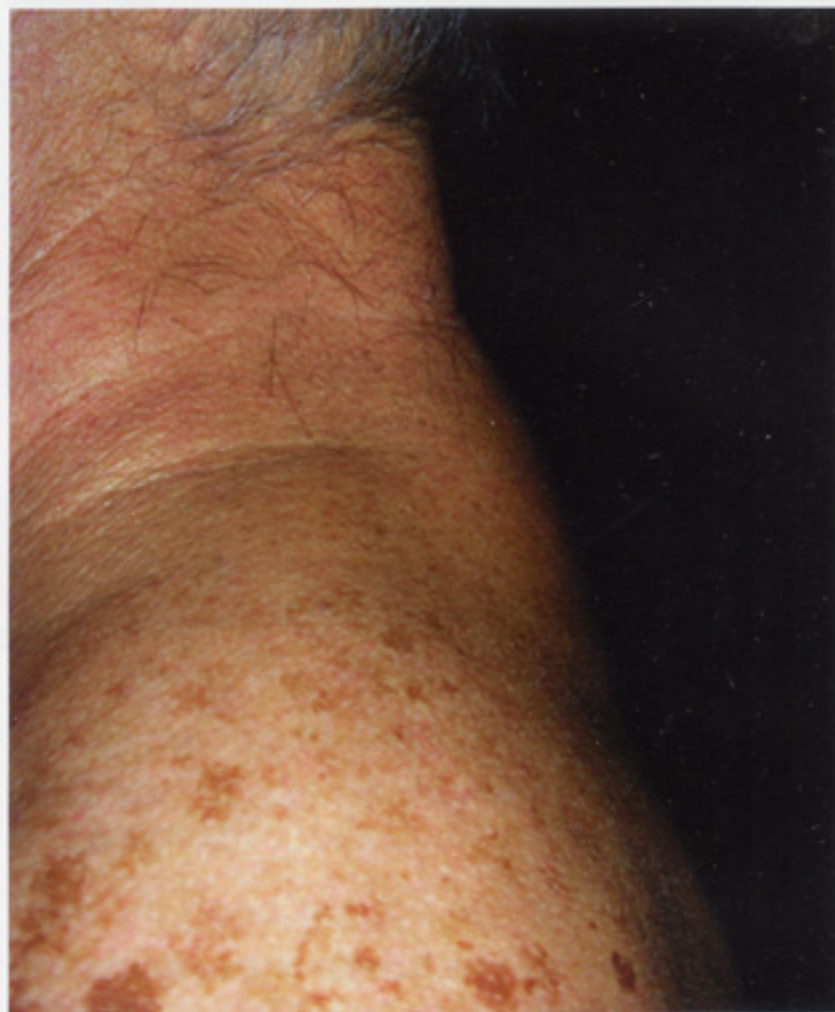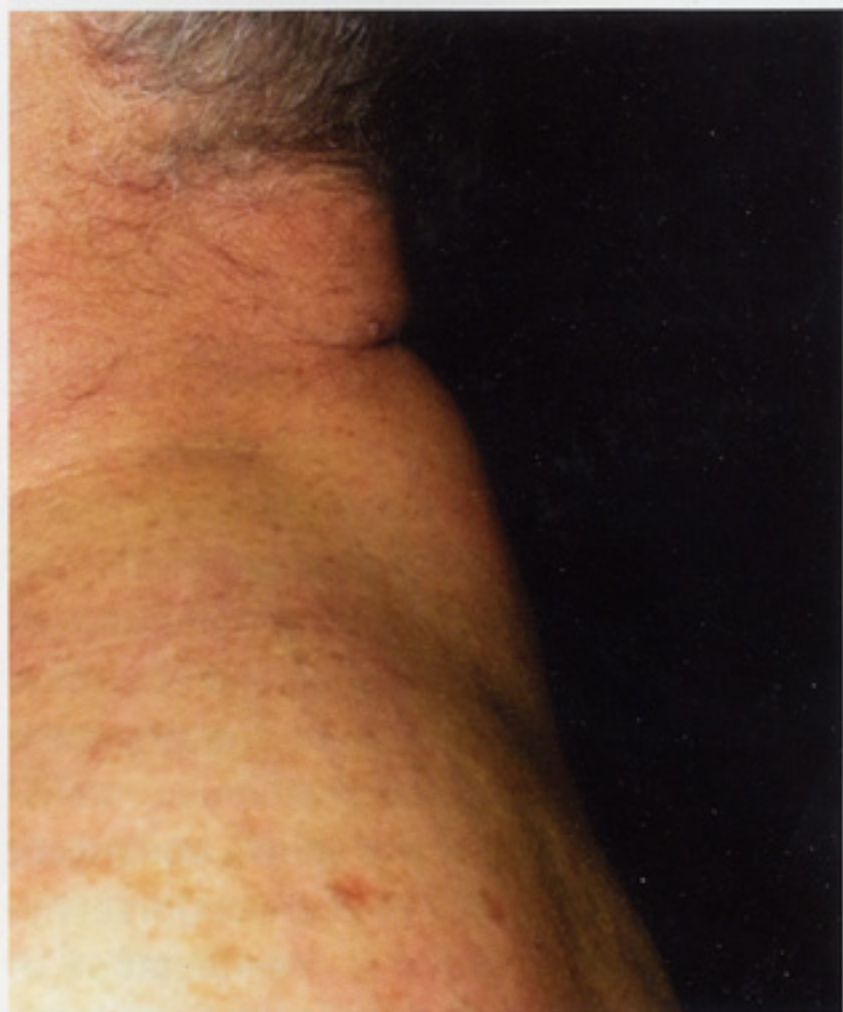Patient was fully explained about no experience about buffalo hump treatment with Aqualyx®, but he accepted the treatment and informed consent was signed.

Before buffalo hump treatment, an ultrasonographic examination, and photographic documentation of the dorsocervical fat pad were performed. Three sit were performed, one per month; in each sit a vial of 8 mL of Aqualyx® was injected using intralipotherapy large area needles (Lipoinject® series) as explained by the producer. At each sit the area to be injected was carefully cleaned with clorexidine 0,2%; sterile gloves were used by the physician, asepsis rules were followed; no antibiotic therapy was performed. After each injection session, a well tolerated light swelling and ecchymosis were referred by the patients which gradually disappear in about 5 days. Not major,

nor minor complication were registered. Clinical improvement was documented by photos and was reported by the patient after each treatment.

Two weeks after last sit a new ultrasonographic examination was performed to assess the result; it showed 2.4 mm reduction of the dorsocervical fat pad.

FIGURES 1 AND 2. Before and after 3 treatment (lateral vision)



FIGURES 3 AND 4. Before and after 3 treatment (frontal vision)

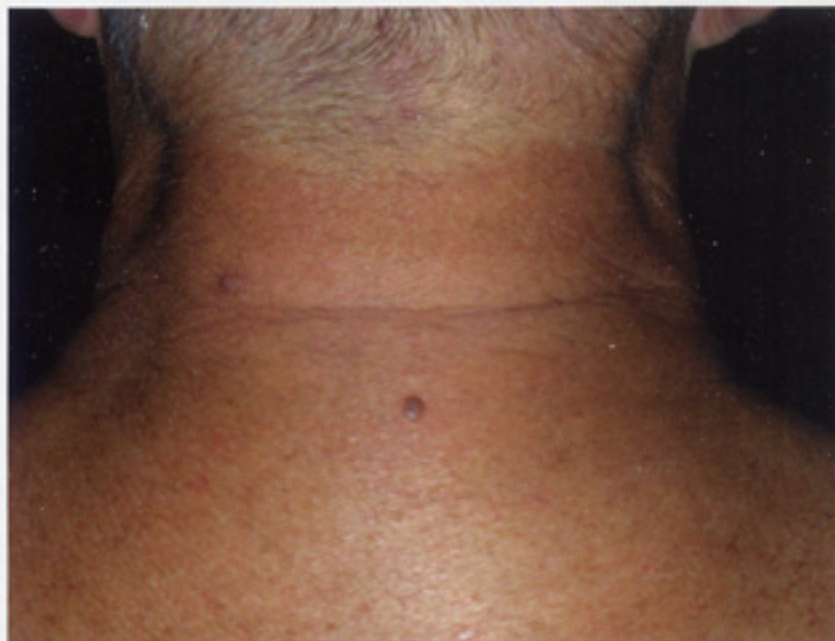
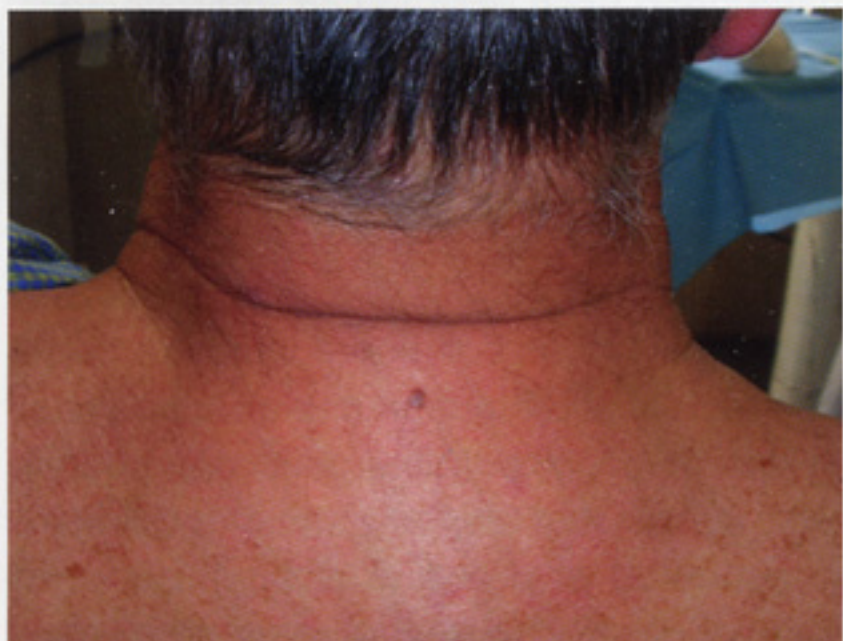

FIGURE 5. Ultrasound measurement of subcutaneous thickness before the treatment

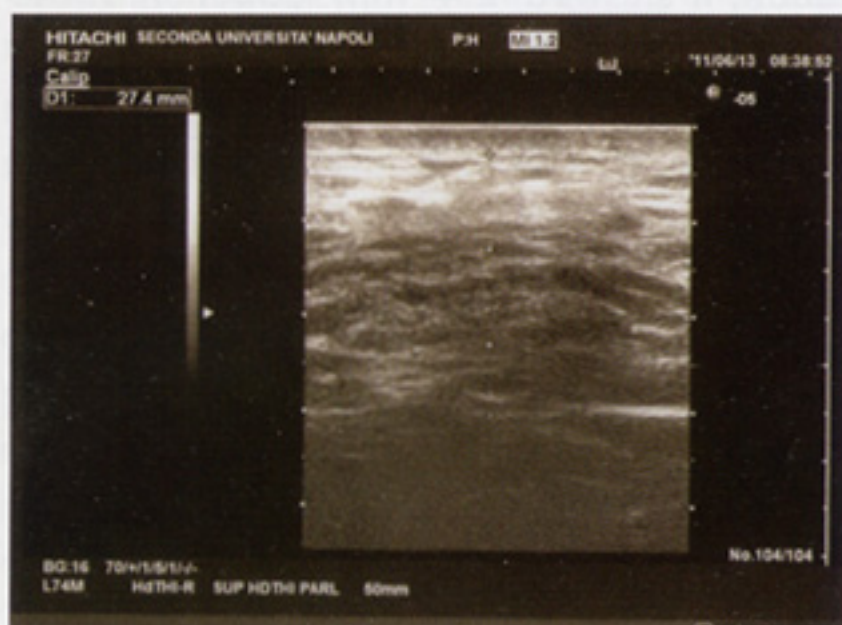
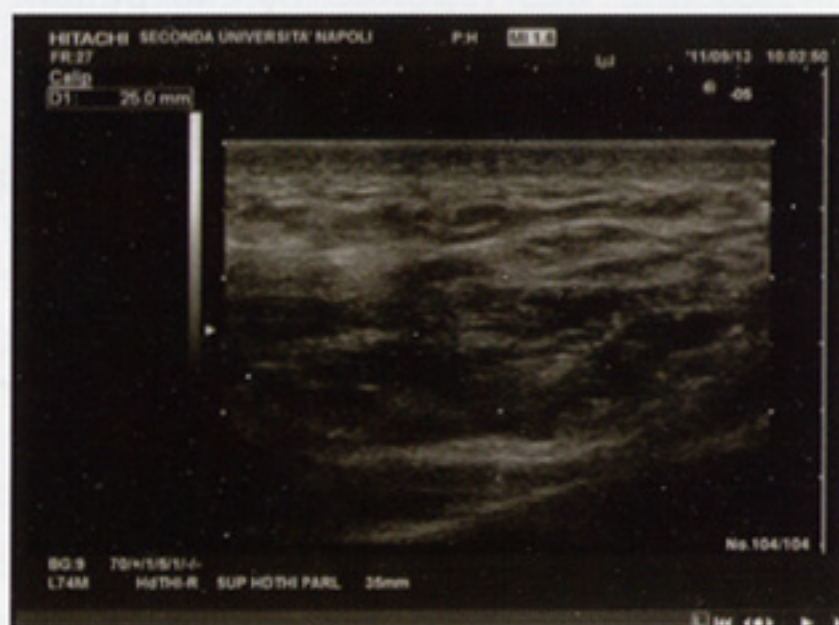

FIGURE 6. The measurement after 3 treatment shows 24 mm subcutaneous thickness reduction.



DISCUSSION

Buffalo hump deformity is a well-described manifestation of HIV-associated lipodystrophy. Multiple studies have attempted to better understand the pathogenesis responsible for the condition, yet the precise mechanism has not yet been determined. Proposed hypotheses have included local effects of increased glucocorticoid production⁽⁵⁾, inhibition of adipocytes differentiation⁽⁶⁾, impaired activity of glucose transporters⁽⁷⁾, and mitochondrial toxicity^(8,9), among others. Although further research efforts are in progress to define the pathologic basis for the condition in the hope of developing prevention and treatment strategies for HIV-associated lipodystrophy, current therapies have been targeted toward specific clinical aspects of the syndrome as a means of relieving patient symptoms.

Treatment for cervicodorsal fat pad (buffalo

hump deformity) enlargement has been challenging, as the hypertrophied fat is notoriously resistant to most attempted therapies. The effects of cessation and alteration of antiretroviral therapies on the presence of the deformity have been studied extensively, but results have not shown consistent improvement in either the cervicodorsal hypertrophy or on the other manifestation of the syndrome^(10,11). Although several medical treatments, including recombinant growth hormone⁽¹²⁾ and anabolic steroids⁽¹³⁾, have been used with varied improvement, until now surgical approaches have been the mainstay of correction of cervicodorsal enlargement.

In the present paper we used an aqueous micro-gelatinous solution containing a biocompatible and biodegradable slow release system and a mix of detergents compounds with a short half life, that attained CE certification and has been in clinical use since 2009 under the brand name Aqualyx® (Ghi-

mas S.p.A., Casalecchio di Reno-BO- Italy), also called Motolese's solution, to reduce the buffalo hump deformity. This solution acts inducing adipocytolysis (lysis of the adipocytes), and is indicated for the non-surgical reduction of localized adipose deposits.

As already shown in literature, structural fat graft seems to be the best option in facial wasting rehabilitation; the use of the peripheral hypertrophied fat, harvested with cannula, let to restore the hypotrophized areas, such as the face, and, in the same surgical step, let to achieve a pleasant body contour. However different results have been reported in literature about the effectiveness of structural fat graft in facial wasting rehabilitation due to the high degree of reabsorption of the transplanted fat ^(14, 15).

Otherwise, Rauso et al., in a recent paper, showed as fat harvested from buffalo hump deformity seems to be a perfect biological filler in facial wasting rehabilitation due to his very low grade of reabsorption⁽¹⁶⁾.

In this report patient refused surgical treatment, so medical treatment were performed. Polyacrylamide gel injection for facial wasting rehabilitation is already shown as a safe and reliable option⁽¹⁷⁾; however for the management of lipohypertrophied areas no medical option were available, so we tried with Aqualyx®.

Ultrasonographic examination showed a slight reduction of the hypertrophied dorsocervical fat pad; clinically the patient was happy with the result achieved.

CONCLUSION

To our knowledge this is the first report of a buffalo hump deformity treated with Aqualyx®, so in selected cases, when patient refuse surgical treatment, the use of Aqualyx® seems to be a safe and effective way to reduce hypertrophied dorsocervical fat pad. A more large scale and double blinded studies are already carried out in order to confirm the efficacy and to better define the adequate posology of the injectable device.

REFERENCES

1. Karon JM, Fleming PL, Steketee RW, De Cook KM. HIV in the United States at the turn of the century. *Am J Public Health* 2001;91:1060.
2. Carr AA. Syndrome of peripheral lipodystrophy, hyperlipidemia, and insulin resistance in patients on HIV protease inhibitors. *AIDS* 1998;12:F51.
3. Heath KV, Hogg RS, Chan KJ, Harris M, Montessori V, O'Shaughnessy MV et al. Lipodystrophy-associated morphological, cholesterol and triglyceride abnormalities in a population-based HIV/AIDS treatment database. *AIDS* 2001;15:231-239.
4. Blanch J, Rousaud A, Martinez E, et al. Factors associated with severe impact of lipodystrophy on the quality of life of patients infected with HIV-1. *Clin Infect Dis* 2004;38:1464-70
5. Chen D, Misra A, Garg A. Clinical review 153: lipodystrophy in human immunodeficiency virus-infected patients. *J Clin Endocrinol Metab* 2002;87:4845-4856
6. Carr A, Samaras K, Chisholm DJ, Cooper DA. Abnormal fat distribution and use of protease inhibitors. *Lancet* 1998;351:1736
7. Murata H, Hruz PW, Mueckler M. Indinavir inhibits the glucose transporter isoform Glut4 at physiologic concentrations. *AIDS* 2002;16:859-863
8. Dalakas MC, Illa I, Pezeshkpour GH, Laukaitis JP, Cohen B, Griffin JL. Mitochondrial

- myopathy caused by long-term zidovudine therapy. *N Eng J Med* 1990;322:1098-1105
9. Chen CH, Vazquez-Padua M, Cheng YC. Effect of anti-human immunodeficiency virus nucleoside analogs on mitochondrial DNA and its implication for delayed toxicity. *Mol Pharmacol* 1991;39:625-628
 10. Roth VR, Kravcik S, Angel JB. Development of cervical fat pads following therapy with human immunodeficiency virus type 1 protease inhibitors. *Clin Infect Dis* 1998;27:65-67
 11. Viraben R, Aquilina C. Indinavir-associated lipodystrophy. *AIDS* 1998;12:F37-F39
 12. Lo JC, Mulligan K, Noor MA, et al. The effects of recombinant human growth hormone on body composition and glucose metabolism in HIV-infected patients with fat accumulation. *J Clin Endocrinol Metab* 2001;86:3480-3487
 13. Gold J, Batterham M. Nandrolone decanoate: use in HIV-associated lipodystrophy syndrome: a pilot study. *Int J STD AIDS* 1999;10:558
 14. Nelson L, Stewart KJ. Experience in the treatment of HIV-associated lipodystrophy. *JPRAS* 2008;61:366-371
 15. Serra-Renom JM, Fontdevila J. Treatment of facial fat atrophy related to treatment with protease inhibitors by autologous fat injection in patients with Human Immunodeficiency Virus Infection. *Plast Reconstr Surg* 2004;114:551-5
 16. Rauso R, Gherardini G, Greco M, Tartaro G. Is buffalo hump fat the perfect filler for facial wasting rehabilitation? Reflection on three cases. *Eur J Plast Surg* 2011;DOI: 10.1007/s00238-011-0581-2
 17. Rauso R, Gherardini G, Parlato V, Amore R, Tartaro G. Polyacrylamide Gel for Facial Wasting Rehabilitation: How many milliliters per session? *Aesthetic Plast Surg*. 2011 Jun 3